

Risk factors and specialized contact lens fitting for post Lasik corneal ectasiaSamuel Tung-Hsing Chiang¹, David Chao-Kai Chang², John Ching-Jen Hsiao^{3,4,*}¹ The Vision Care Institute of Johnson & Johnson, Taipei City, Taiwan² Nobel Eye Clinic, Taipei City, Taiwan³ School of Optometry, Chung Shan Medical University, Taichung City, Taiwan⁴ Department of Ophthalmology, Chung Shan Medical University Hospital, Taichung City, Taiwanjohncejhsiao@yahoo.com.tw

Abstract: Corneal ectasia following Lasik is a devastating complication of laser in keratomileusis (Lasik). The classic clinical sign of the condition is a progressive steepening and thinning of the cornea after excimer laser refractive surgery that reduces both uncorrected visual acuity and corrected visual acuity with spectacle. Risk factors for the development of ectasia after Lasik include high myopia prior to surgery, low residual stromal bed thickness, low preoperative corneal thickness, forme fruste keratoconus and multiple laser enhancements. Management of postoperative ectasia with specialized contact lens remains the main course of treatment for patients who do not wish to go through other surgical options or corneal transplantation. [Samuel Tung-Hsing Chiang, David Chao-Kai Chang, John Ching-Jen Hsiao. **Risk factors and specialized contact lens fitting for post Lasik corneal ectasia.** *Life Sci J.* 2013, 10(1): 45-48] (ISSN:1097-8135). <http://www.lifesciencesite.com>.⁷

Keywords: Corneal ectasia, Laser in keratomileusis(Lasik), Residual stromal bed thickness, Specialized contact lens

1. Introduction

Corneal ectasia after Lasik is a disorder of disruption or alteration in corneal integrity. The condition presents itself with a progressive inferior corneal steepening, an increase in both myopia and astigmatism, and loss of both corrected and uncorrected visual acuities. Corneal ectasia after Lasik has been reported in patients with keratoconus, forme fruste keratoconus, and high myopia.^{1,2} Although rare, the actual incidence may be underreported.³ In views of severe complication caused by ectasia, careful screening of risk factors of patients prior to refractive surgery is no doubt important and essential. There are various types of treatment options for postoperative ectasia, including rigid gas permeable lenses, scleral rigid lenses, hybrid lenses of soft and rigid gas permeable lenses as the non-surgical treatment and corneal ring segment implantation with Intacs, Kera Rings, Cross-linking as the surgical treatment. Currently, the most commonly used management for visual rehabilitation is rigid contact lens; however, there are some patients who cannot tolerate these.⁴ In this article, we will discuss the risk factors and rigid gas permeable fitting techniques for post Lasik ectasia. In addition, monitor and management of a typical post Lasik ectasia patient will also be illustrated.

2. Material and Methods

Best corrected visual acuity was done by using Topcon phoropter. Documenting ectatic condition was done by Dicon topographer (Paradigm Medical,

USA) and keratometry reading via Topcon keratometer. Corneal pachymetry performed by Orbscan II. Contact lenses used are Rose K design rigid gas-permeable lens for keratoconic eye.

3. Results

The significant risk factors for the development of ectasia after Lasik include high preoperative refractive error, forme fruste keratoconus, low preoperative corneal thickness and multiple laser enhancements. In current days, the use of rigid gas permeable lens is the most often used treatment for ectasia. We report the course and the management of a patient with typical post Lasik ectasia developed in her right eye. A 36 year old Asian female with unremarkable health condition had a Lasik refractive surgery done to her both eyes. The pre-operation manifest refraction were $-3.00-1.50 \times 015$ in the right eye and $-1.25-1.00 \times 170$ in the left eye. Both eyes had the corrected vision of 20/25+. The keratometric values were 39.75@003/42.25@093 in the right eye and 39.50@172/41.75@082 in the left eye. Corneal pachymetries (Orbscan II) were 458 μ m in the right eye and 455 μ m in the left eye. Surgery was performed with the Moria microkeratome and the Wavefront guided excimer laser. During the post operation follow-ups, the unaided acuities were 20/25+ OD and 20/25+ OS for 1 week and 1 month time. At the 3 months follow up visit, there was a slightly worse of OD vision to 20/30+ with a minor trace of central island found on topography (Fig. 1).

OS remains unremarkable. The manifest refraction were $-0.50-0.70 \times 012$ in the right eye, and $+0.50-0.50 \times 020$ in the left eye; the keratometric values were $38.25@015/39.25@105$ in the right eye and $38.00@170/39.00@080$ in the left eye at that time. The patient was told to keep up the follow up visits. At the 6 months follow up visit, the patient had noticed significant worsen of her OD vision. The acuity had dropped tremendously to only 20/200 OD and still 20/25⁺ OS.

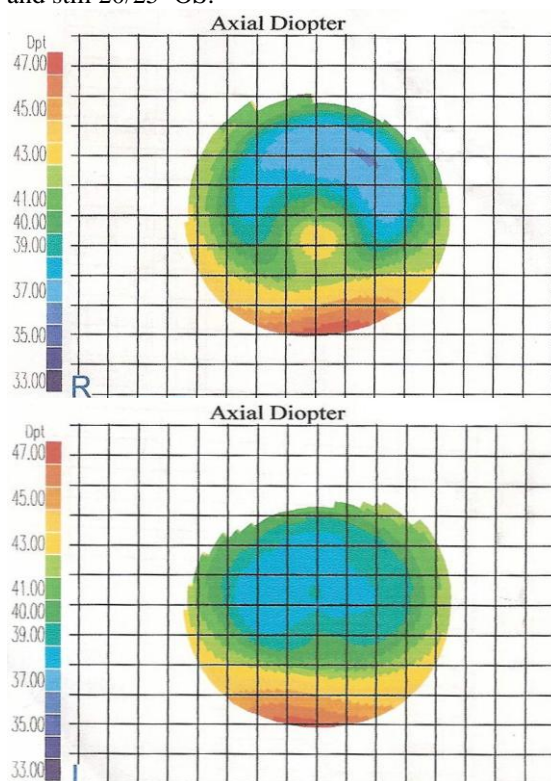


Fig. 1. Three months post bilateral Lasik surgery, a small central island found at OD topography.

Corneal topography was taken (Fig. 2) and confirmed ectasia for her right eye with signs of Fleischer Iron Ring and Vogt's striae present (Fig. 3). Keratometry reading of OD was $63.00@143/64.37@053$. After many trial lens fittings, a rigid lens of Rose K design with parameters of $6.30/-14.75/8.7$ (lens' base curve/ back vertex power/total lens diameter) giving an acuity of 20/40⁺ was ordered and given to the patient (Fig. 4). OS remained unremarkable without any trace of ectasia. The patient was told about the presence of post Lasik ectasia in the right eye and to keep on the lens wear in order to maintain the adequate visual acuity, and hopefully to hinder the progression of the ectasia. At the follow up visits of 9 months and 1 year, the

ectasia of OD appeared to be only minor steeper than before (Fig. 5) and the OD lens fitting relationship with the ectatic cornea remained acceptable.




Fig. 2. Ectasia found on the corneal topography of OD at 6 months post Lasik surgery.

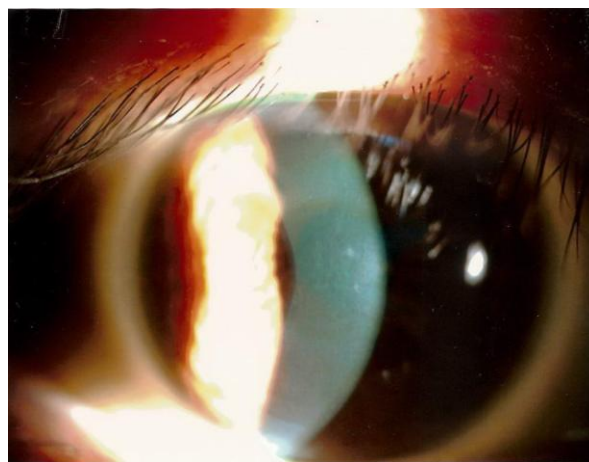


Fig. 3. Fleischer Iron Ring and Vogt's striae on the patient's OD, 6 months post Lasik surgery.

At 2 years post Lasik operation, the patient came back for monitoring her ectasia condition. Both the corneal topography (Fig. 6) and K readings of OD had shown a steeper ectasia. The K readings of OD was $65.62@001/69.87@091$ and the current Rose K lens appeared to be fitted too flat with some over compressed area at the apex. (Fig. 7) A new steeper base curve Rose K rigid lens with parameter of $6.05/-17.00/8.7$ pc-0.1mm in radius was hence ordered for a better lens-cornea fitting relationship. (Fig. 8) The patient was instructed to continue lens wear.

4. Discussion

By definition, ectasia is defined as inferior-topographic steepening of 5 diopters (D) or more

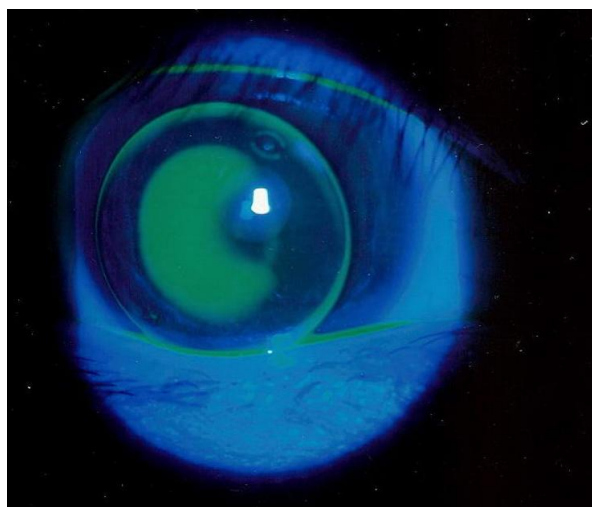


Fig. 4. First rigid lens of Rose-K design fitted on the ectatic cornea at 6 months post Lasik surgery.

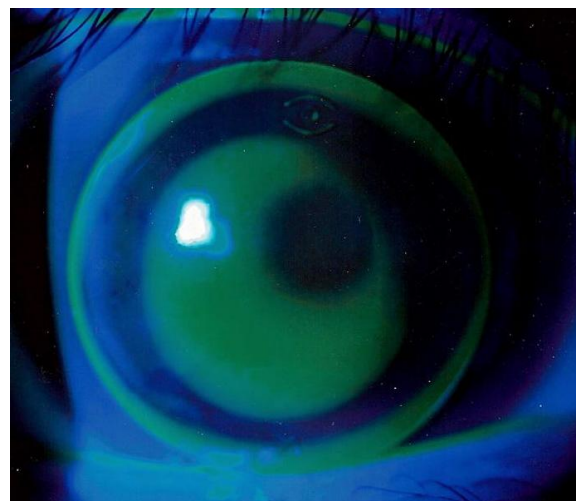


Fig. 7. First rigid lens of Rose-K design on the ectatic cornea at 2 year post Lasik surgery, showing too much compression at the apex.




Fig 5: Ectasia on the corneal topography of OD at 1 year post Lasik surgery.

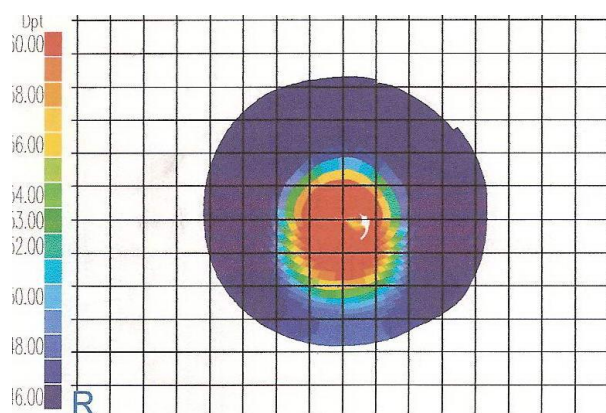


Fig 6: Steeper Ectasia on the corneal topography of OD at 2 year post Lasik surgery.

compared with the immediate postoperative appearance, loss of 2 or more Snellen lines of uncorrected visual acuity, and a change in manifest refraction of 2 or more diopters in either sphere or cylinder.⁵ It is generally accepted that the following conditions are considered the risk factors for the development of post Lasik ectasia.

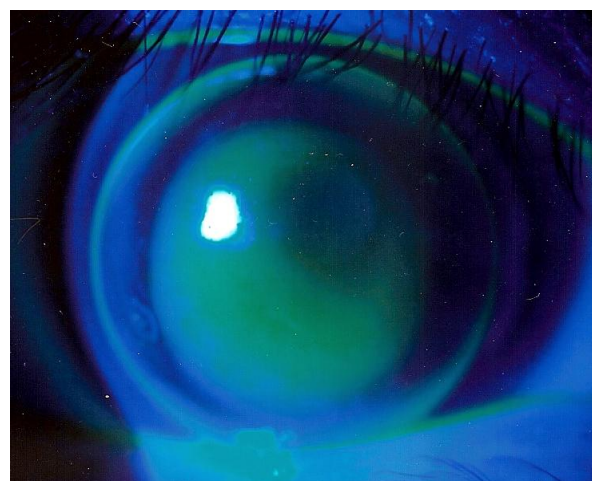


Fig 8: New rigid lens of Ros-K design with a steeper base curve fitted on the ectatic cornea at 2 year post Lasik surgery.

Patients with keratoconus or forme fruste keratoconus: Eyes with keratoconus are known to produce unpredictable refractive results and scarring after radial keratectomy, photorefractive keratectomy, and LASIK.^{6,7} Even with normal spectacle corrected vision, with the aids of corneal topography, we

should look for any trace of steeper paracentral cornea that are steeper than normal, such as in the case of forme fruste keratoconus.

Low preoperative corneal thickness: It is generally recommended that the residual stromal bed thickness of at least 250 μm be maintained to prevent corneal ectasia after Keratomileusis.⁸ The residual stromal bed thickness can be easily calculated by taking the preoperative pachymetry and minus both the predicted flap thickness and total calculated ablation depth.

High myopia (>8 D): It is logical to predict that the patient with high myopia will have low residual stromal bed thickness after tissue ablation than that of less myopic patient.

Multiple laser enhancements: Multiple enhancements were common among post Lasik ectasia cases, but their causative role remains unknown.⁵

The visual impact of postoperative ectasia may range from mild to severe and its progression is often unpredictable. Mild cases have been managed successfully with spectacles; however, most patients develop irregular astigmatism, which limits the efficacy of spectacles.⁴ Rigid contact lens on the hand is able to solve this problem due to the fact that it creates a spherical anterior refractive surface over the ectatic cornea and the tear film provides an optical bridge between the posterior aspect of the contact lens and the irregular cornea, thereby reduces the majority of the irregular astigmatism. In fitting contact lenses for keratoconus, various lens designs should ideally be available for practitioners because no single design will work for every patient. In the case of using Rose K rigid gas-permeable lens, the base curve was determined by averaging the corneal Ks then selecting a lens that was 0.2 mm steeper than the average K⁹ as the starting trial lens to fit. Clinically, the fit of the contact lens was assessed on a slitlamp with the use of a fluorescein dye, and the contact lens fit was judged to be good if there was apical clearance or mild apical touch, good centration, and adequate edge lift.

5. Conclusion

High myopia, low preoperative corneal thickness, sign of keratoconus or forme fruste keratoconus and multiple laser enhancements are the significant risk factors of post Lasik ectasia. Careful screening of these conditions prior to laser in situ keratomileusis (LASIK) may help to reduce the incidence of ectasia. Rigid gas permeable lenses are often sufficient for visual rehabilitation because they are successful in addressing the irregular astigmatism encountered with corneal ectasia.

Corresponding Author:

John Ching-Jen Hsiao, OD, FIACLE.

School of Optometry, College of Medical Sciences and Technology, Chung Shan Medical University, No. 110, Jianguo N. Rd., Taichung City 402, Taiwan.

E-mail: johncjhsiao@yahoo.com.tw

References

1. Lafond G, Bazin R, Lajoie C. Bilateral severe keratoconus after laser in situ keratomileusis in a patient with forme fruste keratoconus. *J Cataract Refract Surg* 2001; 27:1115–8.
2. Argento C, Cosentino MJ, Tytun A, et al. Corneal ectasia after laser in situ keratomileusis. *J Cataract Refract Surg* 2001; 27:1440–8.
3. Koch D. The riddle of iatrogenic keratectasia. *J Cataract Refract Surg* 1999; 25:453–4.
4. Bromley JG, Randleman JB. Treatment strategies for corneal ectasia 2010; 21:255–258
5. Randleman JB, Russell B, Ward MA, Thompson KP, Stulting RD. Risk factors and prognosis for corneal ectasia after Lasik. *American Academy of Ophthalmology* 2003; 110(2):267–275
6. Mamalis N, Montgomery S, Anderson C, Miller C. Radial keratotomy in a patient with keratoconus. *Refract Corneal Surg* 1991; 7:374–6.
7. Ellis W. Radial keratotomy in a patient with keratoconus. *J Cataract Refract Surg* 1992; 18: 406–9.
8. Barraquer JL. *Queratomileusis y Queratofakia*. Bogota: Instituto Barraquer de America, 1980: 405–6.
9. Hsiao JC, Tseng SS. Case report of a rapidly progressing monocular keratoconus over 2 years. *Clin & Refract Optom* 2007; 18(5):141–144

1/1/2013